

Author: Stephanie Scott, M.D., Department of Surgery  
Title: Hyperbaric Oxygen Therapy Outcomes in a Community Hospital

## ABSTRACT

The purpose of this paper is to describe the hyperbaric oxygen therapy (HBOT) outcomes in patients cared for in a community hospital setting. From July 2008 through January 2016, 409 patients have sought HBOT. Of these, 43 have medical conditions that are not treatable using HBOT. Some of these conditions are weight loss, acne, scarring and hair loss. Of the remaining 366 patients, 307 {83.9%} have entered HBOT treatment and 72 are currently in treatment. In the patients that have completed treatment, the medical conditions that have showed improvement are respectively: radiation necrosis 92/104, 88.5%; non-healing wounds 43/66, 65.2%; flap or graft necrosis 10/11, 90.9%; arterial insufficiency 18/24, 75.0%; refractory osteomyelitis or necrosis fasciitis 21/25, 84.0%. There has been one case of idiopathic sudden sensory hearing loss that has been cured and 5 cases lost in follow-up. Keywords: hyperbaric oxygen therapy HBOT outcome

## INTRODUCTION

In the 1660's Henshaw built a sealed chamber, which he called the "Domicilium". Using organ bellows, he controlled the flow of air into the chamber. He believed the acute sufferings of patients could be relieved by hyperbaric therapy. Thus, hyperbaric oxygen therapy [HBOT] was born [1].

HBOT can increase arterial oxygen and tissue tensions to 2000 mm HG and 400 mm Hg respectively [2]. Aside from simple effects of improving O<sub>2</sub> to compromised tissue, HBOT has been documented to mobilize stem cells, increase fibroblastic cell synthesis, augment immune response by increased white blood cells [WBC] healing power, and augment antibiotic effects by inhibiting growth of bacterial pathogens [3 – 8]. Enhancement of oxygen tensions is critical for remodeling bone in chronic osteomyelitis [9]. The free radicals released during radiation therapy directly damages DNA leading to cellular toxicity and thus acute injury of tissues [10]. Vascular endothelial growth factor stimulation restores vascularity to radiation damaged tissues for wound healing in cancer patients [10]. Much of the effects of HBOT are due to its effect on NO which directly imparts cell signal modulators in the inflammation and healing cascade [4]. The majority of research on HBOT has been done in major tertiary care hospitals and national research institutions. The purpose of this paper is to review patient selection and outcome data for HBOT patients in a community hospital setting.

## METHOD

A retrospective review of patients who were treated with hyperbaric oxygen therapy at Monmouth Medical Center, a 400 bed community hospital, from July 2008 through January 2016 was done. Patients were selected for HBOT based on the eligibility criteria as published in the Undersea and Hyperbaric Medicine Society guidelines consisting of 16 approved indications.

1. Acute thermal burn injury
2. Air or gas embolism
3. Arterial insufficiencies
  - a. Central retinal artery occlusion
  - b. Healing enhancement in selected problem wounds
4. Carbon monoxide poisoning singularly or complicated by cyanide poisoning
5. Clostridial Myositis and Myonecrosis (gas gangrene)
6. Comprised grafts and flaps
7. Crush injuries, compartment syndrome, acute trauma injuries
8. Decompression sickness
9. Delayed radiation injury (soft tissue and bone necrosis)
10. Idiopathic sudden sensorineural hearing loss
11. Intracranial abscess
12. Necrotizing soft tissues infections
13. Osteomyelitis (refractory)
14. Severe anemia

Table 1. Approved Indications for HBOT (11)

Exclusion criteria were based on medical contraindications to therapy such as pneumothorax within the last year, COPD with chronic CO<sub>2</sub> retention, and history of bleomycin therapy. Relative contraindications were assessed on individual patient underlying conditions and increased risk of treatment. The reasons for patients who were evaluated, approved and started therapy but did not complete therapy included the lack of insurance coverage, out of pocket costs, the inability to get daily transportation, claustrophobia, or the inability to commit to daily therapy over extended period of time.

The hyperbaric chambers used are single unit chambers with a maximum pressure of 3 ATM. Equipment is rented from Sechrist Corporation with regularly scheduled maintenance provided by the company. Equipment checks are completed by the hospital staff daily prior to starting patient care.

The primary end points were completion of therapy, healing of wound, and resolution of symptoms. These end points varied slightly based on indication for treatment. For flap/graft necrosis, non-healing wounds, osteomyelitis, and necrotizing fasciitis, end points were measured by degree of wound healing. This was based on evidence of increased vascularity by presence of granulation tissue in the wound bed and decrease in size of the wound. Wounds were measured and photographed weekly in order to maintain consistency in records. For radiation injuries including hematuria, urinary retention, radiation esophagitis, and neuropathy, outcomes were based on patient self-reporting resolution of symptoms such as decreased hematuria, improvement on the 1-10 pain scale, less nocturnal voiding, and improved tolerance of foods (12). Failing treatment was defined as no visible wound improvement after 20 sessions or no improvement in symptoms after 40 sessions.

Tabulation of data was done using Microsoft Excel. IRB approval was obtained for this retrospective study.

## RESULTS

A total of 409 patients were referred for treatment. There were 253 males (61.9%) and 156 females (38.1%). Of the referred patients, 366 patients met the criteria to undergo hyperbaric oxygen therapy; 307 patients (83.9%) began therapy; 234 (76.2%) completed therapy.

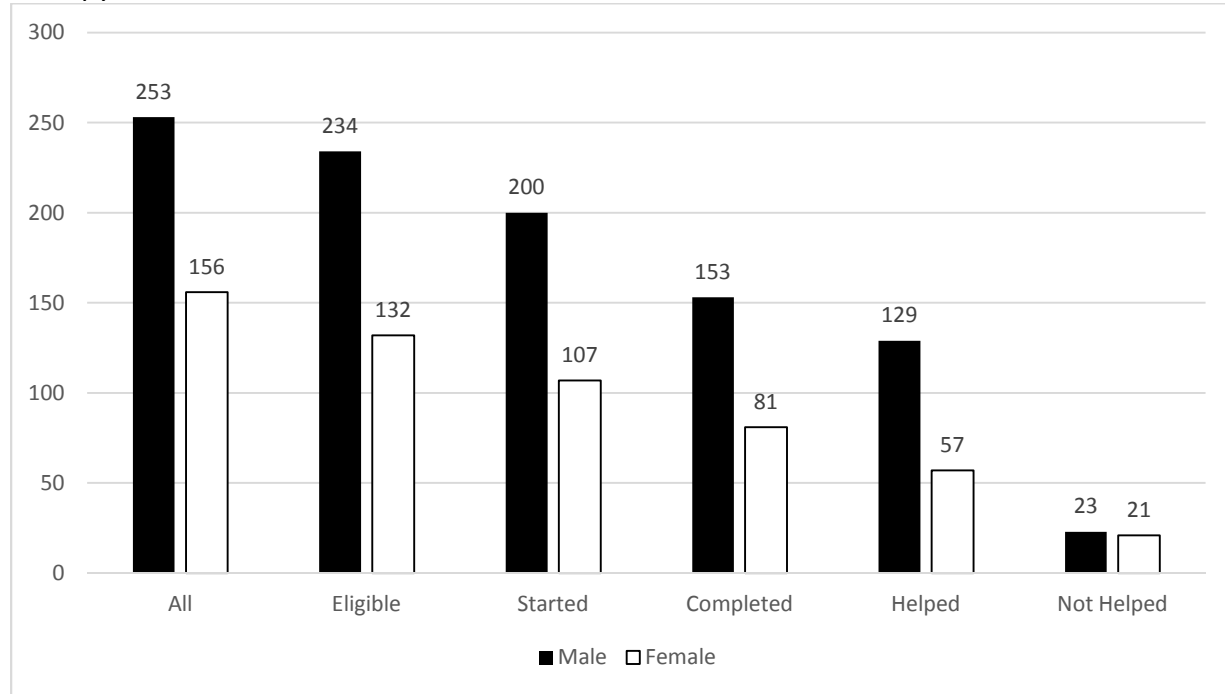


Figure 1. Outcome by Gender

Patients were referred for treatment of radiation injury (148, 36.2%), non-healing wounds (137, 35.5%), flap/graft necrosis (18, 4.4%), arterial insufficiency (48, 11.7%), osteomyelitis/necrotizing fasciitis (49, 12.0%) and idiopathic sudden sensorineural hearing loss (1, 0.2%).

Overall, of the 234 patients who completed treatment, 79.5% (186) reported significant improvement of their symptoms or had complete healing of their wounds. When analyzed by gender, 65.4% (153) of the males reported success with treatments whereas only 34.6% (81) of the females reported success. Of the 234 patients who showed improvement, those who had radiation injury, 92/104 (88.5%); non-healing wounds 43/66, 65.2%; flap or graft necrosis 10/11, 90.9%; arterial insufficiency 18/24, 75.0% and refractory osteomyelitis or necrosis fasciitis 21/25, 84.0%. The one patient referred for sudden hearing loss reported complete resolution of symptoms.

	# With Improvement	# Completed Therapy	Percent
Radiation injury	92	106	86.8%
Non-healing wound	43	66	55.2%
Flap/Graft necrosis	10	11	90.9%
Arterial insufficiency	19	25	76.0%
Osteo/ Nec fasciitis	21	26	80.8%
ISSNHL	1	1	100%

Table 1. Improvement after completing therapy

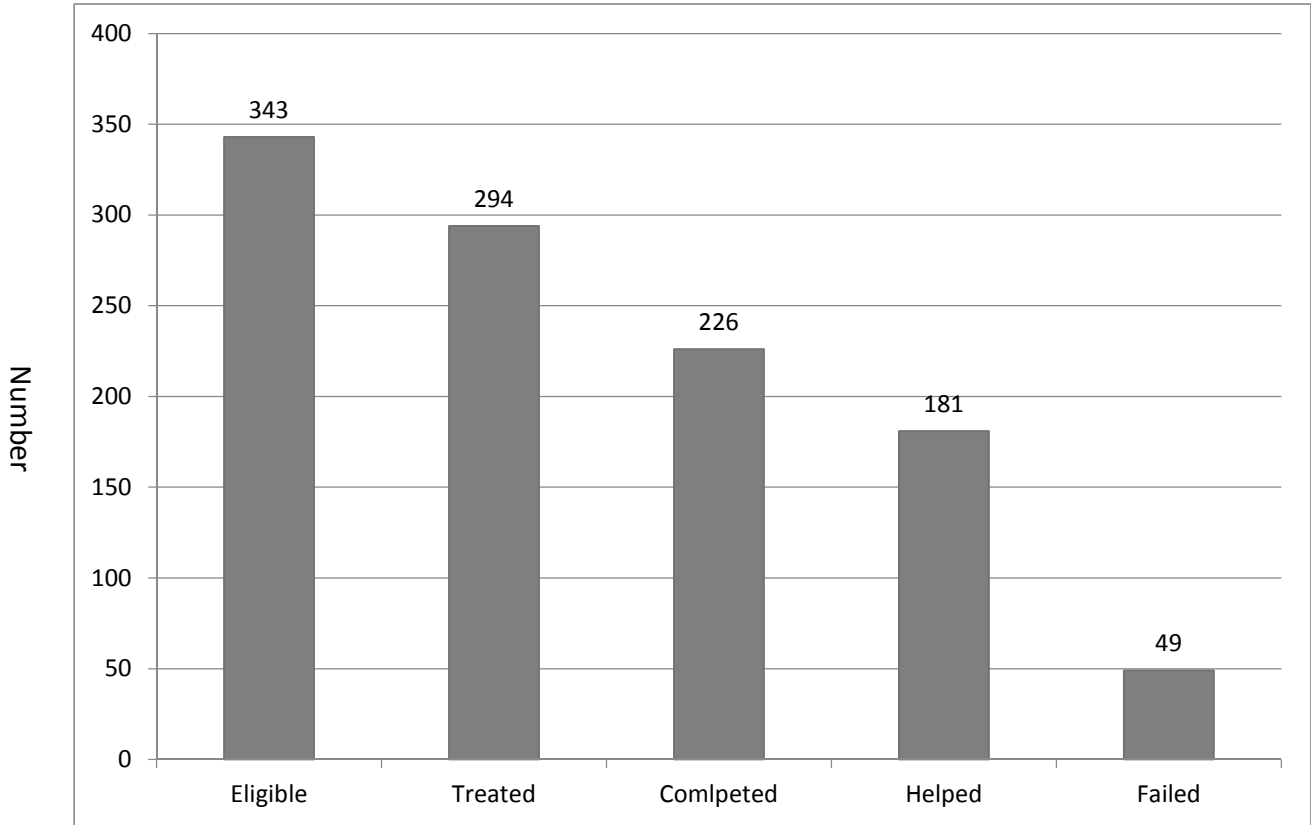


Figure 2. Eligibility, Treated, Completed and Outcome

## DISCUSSION

A meta-analysis published in 2003 reviewed 57 studies and 34 case series with a total of over 2000 patients treated with HBOT for various indications found overall that study qualities were poor with low patient numbers in many individual trials. In addition, conclusions suggested that HBOT may be effective in some wound types but power was poor for determining whether patients would benefit from HBOT (13).

Previously published results from HBOT trials were conducted by large tertiary academic hospitals, university medical centers, or national institutions. We compared our results in individual categories with results published previously in order to validate HBOT in a community hospital. In addition, with our results, we hope to add to the number of published results in order to further strengthen the data and argument for use of HBOT.

### Radiation Injury:

The damage caused by radiation to tissues has been intricately studied and found to be largely due to vascular changes characterized by an obliterative endarteritis (10). This damage, known as the fibro atrophic effect, begins at the time of radiation and primarily involves the release of fibro genetic cytokines as well as the depletion of parenchymal and stem cells thus leading to tissue atrophy. The benefits of HBOT in radiation necrosis are three-fold. First, HBOT has been shown to stimulate angiogenesis and thereby improve tissue oxygenation. Secondly,

the stromal fibrosis that occurs in scarring from radiation is reduced. And thirdly, HBOT stimulates a mobilization and induction of stem cells within irradiated tissues in order to implement growth of healthy functional tissue rather than fibrotic scar tissue (10).

It has been reported that as high as 33% of patients referred for HBOT are for treatment of radiation injury and necrosis (10). Radiation injury can be divided into 2 categories: acute and subacute injury. In acute radiation injury, damage is due to direct and immediate cellular toxicity caused by free-radical mediated damage to the DNA (10). Subacute (a delay onset of 6 months or greater) radiation injury includes conditions presenting later such as radiation pneumonitis and spinal cord demyelination. The symptoms of these conditions generally persist several weeks to months and are usually self-limiting. However, during the course of the disease, the symptoms can be debilitating and can ultimately evolve to delayed injuries. Thus, both acute and subacute radiation injuries are indications for treatment with HBOT.

In our series of patients with radiation injury, 92 patients (67.2%) showed improvement after completing HBOT treatments. In 1997, It was reported that in a series of 15 patients, 12/15 (80%) healed completely; 2 healed partially, and 1 did not heal at all. In the control group of 15 patients, only 7 showed significant healing, 2 progressed to life threatening hemorrhage, and ultimately 1 patient exsanguinated (14). In a separate review of 4 published case series, the largest series enrolled 32 patients. Of these, 8 (25%) had complete resolution of radiation injury. Overall, the 32 patients all experienced some improvement in symptoms (3). In another study by the same authors, 6 out of 8 patients with radiation necrosis went on to heal without surgical intervention (15). The review of literature shows healing with HBOT but the trial numbers are low.

#### Non-healing Wounds:

Patients with diabetes mellitus and peripheral vascular disease are among those at significantly increased risk of developing ulcers and infections that progress to chronic, non-healing wounds. The pathophysiology behind the breakdown of the integument border can be traced back to hypoxia of the tissue. The vascularity is not only injured by the chronic disease thus inhibiting oxygen delivery, but the baseline hypoxia is compounded by the decreased oxygen supply due to increased cellular activity as the body is constantly attempting to heal (16). Multiple facets of the healing process are impaired by the decreased oxygen tension. Wound healing requires oxygen tension of 30-40mmHg (17). Below this level, phagocytosis by macrophages is impaired, oxidative killing of bacteria is decreased, and deposition of new collagen by fibroblasts is diminished (16). By treating patients with 100% oxygen at pressures greater than 1 atm, the oxygen tension in the wounded tissue is brought up to the levels needed to facilitate fibroblast proliferation, angiogenesis, and wound healing (6, 18).

In reviewing the literature, chronic wounds have varied results. This could be that each series uses a different outcome measurement to indicate successful treatment. In our study, we counted evidence of healing as successful outcome; this included decrease in wound size, granulation tissue formation in wound beds, and improved vascularity of the surrounding tissue. Overall, we saw a 30.3% (40/132) improvement rate. Other reviewed case series had higher outcome percentages but had significantly smaller numbers of patients enrolled in HBOT. In a study with 17 HBOT patients, there was a 37.5% reduction in wound surface area while in the control group, only 2.7% of patients experienced wound healing (19). In another study that included 10 patients, 5 in the control group and 5 undergoing HBOT, outcomes were

measured by progression of wound requiring amputation or complete healing. Of the patients treated with HBOT, 4/5 (80%) experienced complete healing while only 1 of 5 of the control group experienced complete healing; no amputations required in either group (20). A retrospective series of 20 patients undergoing HBOT, 75% of patients progressed to complete healing (21). In a more recent trial, outcomes of 29 patients treated with HBOT were divided into 4 specific categories indicating a range of response to treatment but were based on subjective improvement rather than objective measurements (22). Wound responses were described as excellent (greater than 90% decrease in wound size), good (greater than 30% decrease in wound size), fair (healing of the wound with additional interventions), or poor (less than 30% decrease in wound size). They reported 6 patients with excellent improvement, 8 patients as good, 11 as fair, and 4 as poor.

Infections developed in 5/80 (6%) of patients with flap or graft necrosis who underwent HBOT. In 10/18 (55%) in the control group; wound dehiscence occurred in only 9/80 (11%) undergoing HBOT but in 38/80 (48%) in the control group; and delayed healing 9/80 (11%) in HBOT group but 44/80 (55%) in control (23). As early as 1967, 48 patients (64%) who received HBOT had an improved survival rate of grafts while only 17% in control showed improvement (24). In patients with arterial insufficiency, HBOT improved the overall healing rate in 82 patients (49.3%); reduced the overall amputation rate to 17.1% and of those that healed, none required amputation (25). Of 38 patients who had osteomyelitis and underwent HBOT, 34/38 (89%) were free of these conditions at 3 months (26). In 61 patients who suffered from idiopathic sudden sensorineural hearing loss and who were also treated with vasodilatation medications, if HBOT was started within 10 days of onset, the improvement rate was 65.9%, but if HBOT was started after 10 days the improvement was only 38.9% (27).

There are, however, other studies that report mixed or no improvements with HBOT in various conditions (28-30). These findings could be due to various causes which could include insufficient sample size, subjective definitions of improvements and bias.

## CONCLUSION

HBOT is effective regardless if it is used in tertiary or community hospital settings. While this is not comprehensive review of all case series and trials published on outcomes of patients treated with hyperbaric oxygen, it does reiterate that results provide positive support for HBOT despite the case series and prospective controlled trials being small. While our retrospective review includes a larger number of patients enrolled in treatment, there is still the need for more randomized controlled studies with greater power. Nevertheless, this study clearly demonstrates that HBOT is effective in a community hospital setting.

## REFERENCES

1. Neuman TS, Thom SR. Physiology and Medicine of Hyperbaric Oxygen Therapy. Philadelphia PA: Saunders; 2008.
2. Tibbles PM, Edelsberg JS, Hyperbaric oxygen therapy: N Engl J Med, 1996;334:1642-8.
3. Feldmeier JJ, Hampson NB. A systematic review of the literature reporting the application of hyperbaric oxygen prevention and treatment of delayed radiation injuries: An evidence based approach. Undersea Hyperb Med 2002;29:4-30.

4. Thom SR. Hyperbaric oxygen – its mechanisms and efficacy. *Plast Reconstr Surg*. 2011;127:131S-41S.
5. Gordilla Gm, Seri CK. Revisiting the essential role of oxygen in wound healing. *Am J Surg* 2003;186:259-63.
6. Roth RN, Weiss LD. Hyperbaric oxygen and wound healing. *Clinics in Dermatology*. 1994;12:141-56.
7. Kaye D. Effect of hyperbaric oxygen on Aerobic bacteria in vitro and in vivo. *Exp Biol Med* 1967;124:1090-3.
8. Mader JT, Brown GL, Guckian JC, Wells CH, Reinartz JA. A mechanism for the amelioration by hyperbaric oxygen of experimental staphylococcal osteomyelitis in rabbits. *J Infect Dis*. 2008;142:915-22.
9. Esterhai JL Jr, Pisrello J, et al. Adjunctive hyperbaric oxygen therapy in the treatment of chronic refractory osteomyelitis. *J Trauma* 1987; 27: 763-68.
10. Feldmeier JJ. Hyperbaric oxygen therapy and delayed radiation injuries (soft and bony necrosis): 2012 update. *Undersea Hyperb Med* 2012;39:1121-39.
11. Undersea and Hyperbaric Medical Society web site. <https://www.uhms.org/hbo-indications.html>. (34/4/2016)
12. McCaffery M, Beebe A. *Pain: clinical manual for nursing practice*. St. Louis Mo: Mosby 1989.
13. Wang C, Schwaitzberg S, Berliner E, Zarin DA, Lau J. Hyperbaric Oxygen for Treating Wounds: A Systematic Review of the Literature. *Arch Surg*. 2003;138(3):272-79.
14. Neovius EB, Lind MG, Lind FG. Hyperbaric oxygen therapy for wound complications after surgery in the irradiated head and neck: a review of the literature and a report of 15 consecutive patients. *Head Neck*. 1997;19:315-22.
15. Feldmeier JJ, Heimbach RD, Davolt DA, Court WS, Stegmann BJ, Sheffield PJ. Hyperbaric oxygen as an adjunctive treatment for delayed radiation injury of the chest wall: a retrospective review of twenty-three cases. *Undersea Hyperb Med* 1995;22:383-93.
16. Goldstein LJ. Hyperbaric oxygen for chronic wounds. *Dermatologic Therapy* 2013;26:207-14.
17. Tandara AA, Mustoe TA. Oxygen in wound healing – more than a nutrient. *World J Surg*. 2004;28:294-300.
18. Marx RE, Ehler WJ, Tayapongsak P, Pierce LW. Relationship of oxygen dose to angiogenesis induction in irradiated tissue. *Am J Surg* 1990;160:519-24.
19. Hammarlund C, Sundberg T. Hyperbaric oxygen reduced size of chronic leg ulcers: a randomized double-blind study. *Plast Reconstr Surg* 1994;93(4):829–34.
20. Zamboni WA, Wong HP, Stephenson LL, Pfeifer MA. Evaluation of hyperbaric oxygen for diabetic wounds: a prospective study. *Undersea Hyperb Med*. 1997;24(3):175-79.
21. Wattel F, Mathieu D, Coget JM, Billard V. Hyperbaric oxygen therapy in chronic vascular wound management. *Angiology*. 1990;41(1):59-65.
22. Ueno T, Uchida E, Yokota H, Kawana S, Evaluation of hyperbaric oxygen therapy for chronic wounds, *J Nippon Med Sch*. 2014;81:4-11.
23. Marx RE. *Clinical applications of hyperbaric oxygen*. Hyperbaric Medicine Practice. Flagstaff, AZ: Best Publishing Co; 1994: 460-62.
24. Perrins DJ. Influence of hyperbaric oxygen on the survival of split skin grafts. *Lancet*. 1967;1(7495):868-71.

25. Heyboer M, Grant WD, Byrne J, et al. Hyperbaric oxygen for the treatment of non-healing arterial insufficiency ulcers. *Wound Repair Regen.* 2014;22(3):351-55.
26. Davis JC, Hechman JD, DeLee FJ, Buckwold FJ. Chronic nonhematogenous osteomyelitis treated with adjunct hyperbaric oxygen. *J Bone Joint Surg* 1986; 68: 1210-17.
27. Holy R, Navara M, Dosel P, Fundova P, Prazenica P, Hahn A. Hyperbaric oxygen therapy in idiopathic sudden sensorineural hearing loss (ISSNHL) in association with combined treatment. *Undersea Hyperb Med.* 2011;38(2):137-42.
28. Hassan Z, Mullins RF, Friedman BC, Shaver JR, Bandigi C, Alam B, Mian MAH. Treating necrotizing fasciitis with or without hyperbaric oxygen therapy. *Undersea Hyperb Med.* 2010; 37:115-23.
29. Jallali N, Withey S, Butler PE. Hyperbaric oxygen as adjuvant therapy in the management of necrotizing fasciitis. *Am J Surg.* 2005;189(4):462-6.
30. Shupak A, Shoshani O, Goldenberg I, Barzilai A, Moskuna R, Bursztein S. Necrotizing fasciitis: an indication for hyperbaric oxygenation therapy? *Surgery.* 1995;118(5):873-8.